

# EVALUATION AND TREATMENT OF SWALLOWING DISORDERS

JERI A. LOGEMANN

*Northwestern University, Evanston, IL*

Over the past 40–50 years, speech-language pathologists have worked with cerebral-palsied infants and young children on their oral manipulation of food as a precursor to oral motor control for speech (Cruickshank, 1966; Morris, 1977; Westlake & Rutherford, 1961). This feeding therapy focused on the reduction of abnormal oral reflexes and the establishment of oral motor skills needed for food to be moved in the mouth, chewed, and prepared for swallowing. In more recent years, as speech-language pathologists have become more involved in the management of communication disorders in medical settings, they have turned their attention increasingly to the diagnosis and management of swallowing disorders in these patients (Aguilar, Olson, & Shedd, 1979; Logemann, 1983; Logemann & Bytell, 1979).

## FEEDING AND SWALLOWING

The distinction between feeding and swallowing is often difficult to discern from the literature. Generally, the term *feeding* relates to the oral manipulation of food prior to the initiation of the swallow itself and also includes the oral or voluntary stage of the swallow, which involves tongue propulsion of the bolus of food toward the pharynx. *Swallowing* is a broader term, encompassing those aspects of feeding just described but also including the trigger of the swallowing reflex and the pharyngeal stage of the swallow, as well as the esophageal stage of deglutition. Thus, *swallowing* is the term used by clinicians who work with patients whose oral and pharyngeal stages of deglutition are impaired.

Swallowing disorders, or dysphagia, may result from anatomic abnormalities in the oral cavity, pharynx, larynx, or esophagus or from physiologic disturbances in the control of these structures (Donner & Silbiger, 1974; Kirchner, 1967; Logemann, 1983). These disorders may be congenital or may be caused by trauma, surgery, or neurologic damage of sudden or gradual origin (Logan & Bosma, 1967; Logemann & Bytell, 1979; Shedd, Scatliff, & Kirchner, 1960; Silbiger, Pikielney, & Donner, 1967). Swallowing disorders, as they are defined here, do not include the entity known as “tongue thrust,” in which the patient’s tongue apparently pushes forward to initiate the swallow, rather than upward and backward. Unlike tongue thrust, the types of swallowing disorders described here have a clear anatomic or physiologic base.

## NORMAL SWALLOWING

Normal swallowing involves fine neuromotor coordination of the upper aerodigestive tract and both cortical and brain stem control (Miller, 1982). Normal swallowing is divided into four phases: (a) the oral preparatory phase, in which food is manipulated in the mouth, tasted, broken down into a consistency ready for swallowing, and brought back into a single ball or bolus by the tongue in preparation for the swallow; (b) the oral phase, in which the tongue propels the bolus backward; (c) the pharyngeal phase, or reflexive phase of the swallow, in which the bolus moves through the pharynx; and (d) the esophageal stage, in which the bolus moves through the esophagus and enters the stomach (Ardran & Kemp, 1951; Bosma, 1957; Mandelstam & Lieber, 1970; Miller, 1982; Negus, 1949; Sessle & Hannan, 1976). Each of these phases is characterized by specific physiologic patterns.

### *The Oral Preparatory Stage*

Normally, the oral preparatory stage of deglutition involves five neuromotor behaviors: (a) lip closure to keep the food in the mouth anteriorly; (b) tension in the buccal and labial musculature sufficient to close the lateral and anterior sulci, or pockets between the facial musculature and facial skeleton, so that food does not fall into these sulci during chewing, but rather falls medially onto the tongue; (c) a circular or rotary, lateral movement of the jaw to crush food; (d) a rolling, lateral motion of the tongue to pick food up as it comes off the teeth, mix it with saliva, and roll it back onto the teeth; (e) an active pulling forward of the soft palate to seal food in the oral cavity posteriorly, and widen the nasal airway (Logemann, 1983; Miller, 1982; Robbins, Logemann, & Kirchner, 1982; Shedd, Kirchner, & Scatliff, 1961). The most important of these five activities is tongue mobility, which facilitates mastication. Without normal tongue range of motion and control, the patient will be unable to chew normally.

At the end of the oral preparatory phase, the tongue forms the food into a single ball or bolus, pulling the food together from around the oral cavity. The tongue then shapes itself around the bolus in a contour similar to that assumed for production of an isolated [ʃ] sound. That is, the sides of the tongue are elevated to contact the lateral alveolar ridge, and a groove is formed down the middle of the tongue in which the bolus is held (Logemann, 1983; Sessle & Hannan, 1976). All of this activity is voluntary and under cortical control. At this point, the oral stage of the swallow is about to be initiated.

### *The Oral Stage*

The oral phase of the swallow begins when the tongue propels the bolus posteriorly in an upward and backward rolling motion. The tongue squeezes the food along the palate until the bolus reaches the anterior faucial arches. It is at this

point that the swallowing reflex triggers. It is clear that the tongue activity to initiate the voluntary or oral phase of the swallow contributes to triggering the swallowing reflex. This represents cortical input into the triggering of the reflexive swallow (Miller, 1982). The oral phase of the swallow is terminated when the swallowing reflex triggers at the anterior faucial arch. The normal duration of the oral phase of the swallow is approximately 1 s, which does not vary significantly with food consistency, age, or sex of the individual (Blonsky, Logemann, Boshes, & Fisher, 1975; Mandelstam & Lieber, 1970).

### *The Swallowing Reflex*

The swallowing reflex triggers from the ninth cranial (or glossopharyngeal) nerve (Pommerenke, 1928). Impulses from this nerve are carried to the reticular formation in the brain stem where the swallowing center is located (Holstege, Graveland, Bijker-Biemon, & Schuddeboom, 1983; Miller, 1982). The swallowing center is immediately adjacent to the respiratory center so there is close coordination between these two functions. During the split second of the reflexive swallow, respiration is halted. The pharyngeal phase of the swallow begins when the swallowing reflex is triggered.

The reflex center in the brainstem should be thought of as a programming center, which organizes and triggers a variety of neuromotor behaviors to occur in the pharyngeal stage of the swallow. Without normal triggering of the swallowing reflex, none of these neuromotor behaviors will occur. If the swallowing reflex center is intact, there still may be damage to the structures of the aerodigestive tract or their innervation so that one or more of the neuromotor behaviors in the pharynx cannot occur normally. Thus, there may be a disorder of the swallowing reflex or a disorder in one or more of the components which actualize the reflex (Logemann, 1983).

It is important to note also that the swallowing reflex is very different from the other reflexes triggered in the oral cavity. Whereas the gag reflex and the palatal reflex can be triggered by direct contact to various areas of the oral cavity, the swallowing reflex cannot be so triggered (Miller, 1982; Sessle & Hannan, 1976). There is no point in the oral cavity which the clinician can touch and elicit a swallow. Instead, the mechanism of triggering the swallowing reflex is a complex one involving tongue movement and sensory input from the posterior oral cavity as the bolus makes contact with the anterior faucial arch, the posterior faucial arch, and the posterior pharyngeal wall.

### *The Pharyngeal Stage*

When the swallowing reflex triggers, it marks the beginning of the pharyngeal stage of the swallow, and it programs four neuromotor activities to occur. These neuromotor components are (a) velopharyngeal closure to close the nasal cavity and prevent food from entering the nose; (b) peristaltic contraction in the pharyngeal constrictors to squeeze the bolus through the pharynx; (c) airway protection, which involves two dimensions of movement—laryngeal elevation and laryngeal closure;

and (d) cricopharyngeal relaxation to allow the bolus to pass from the pharynx into the esophagus (Ardran & Kemp, 1951, 1956; Bosma, 1957; Doty & Bosma, 1956; Mandelstam & Lieber, 1970; Miller, 1982; Negus, 1949; Shedd et al., 1961). These four neuromotor activities are triggered or programmed by the swallowing reflex. The entire pharyngeal phase of the swallow lasts a maximum of 1 s regardless of food consistency swallowed or age or sex of the patient (Blonsky et al., 1975; Mandelstam & Lieber, 1970).

Each of the four neuromotor activities that occur in the pharyngeal phase of the swallow does not last for the entire duration of the pharyngeal stage, however. Instead, each action occurs only during that period in which the bolus of food passes the relevant portion of the pharynx. For example, velopharyngeal closure occurs only during the fraction of a second in which the bolus passes the opening into the nasal cavity. Once the bolus has neared the mid pharynx, the soft palate begins to lower. Similarly, laryngeal closure to protect the airway from the entry of food does not last for the entire duration of the pharyngeal phase of the swallow, but remains closed only for the fraction of a second that the bolus passes the laryngeal inlet. Thus, each of the neuromotor components of the pharyngeal phase of the swallow occurs very rapidly, lasting for just a fraction of a second (Curtis, Cruess, Dachman, & Mass, 1984; Fabiszak, personal communication, 1984; Laderta, personal communication, 1984).

Another important point must be made about the pharyngeal transit of the bolus of food. There are two anatomic areas of the pharynx often not included in discussions of the anatomy of the speech mechanism: the valleculae and the pyriform sinuses. The valleculae is the space formed between the base of the tongue and the epiglottis, as shown in Figure 1. The lingual tonsils are located at the base of the tongue and so are located in the valleculae. The valleculae is generally described as a single space or pocket, but in fact it is partially divided by the hyoepiglottic ligament, which attaches the epiglottis to the hyoid bone.

Two other pockets or spaces in the pharynx are formed by the attachment of the inferior constrictors to the larynx. As the fibers of the inferior constrictor come around and forward from the posterior pharyngeal raphe, they attach to the laryngeal cartilage anteriorly and laterally, forming spaces between the cartilage and the muscle fibers laterally and posteriorly. These pockets are the pyriform sinuses, as shown in Figure 2. Together, the valleculae and the pyriform sinuses are known as the pharyngeal recesses. During the normal swallow, the bolus divides at the valleculae and half of the food proceeds down each side of the pharynx, and through each of the pyriform sinuses. The cricopharyngeus muscle or upper esophageal sphincter (UES) is located at the bottom of the pyriform sinuses. When the cricopharyngeus muscle relaxes, the bolus of food on the two sides joins to enter the esophagus.

### *The Esophageal Stage*

Once the bolus has passed through the cricopharyngeus muscle at the base of the pharynx, it has entered the esophageal phase of the swallow, which involves

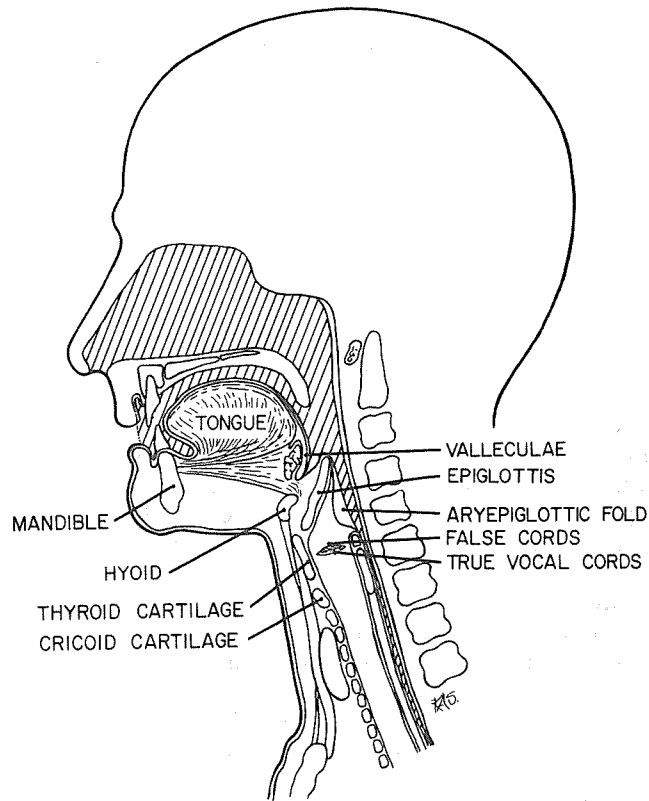


FIGURE 1. Mid saggital section of the head and neck. (From Logemann, 1983; © College-Hill Press, reprinted by permission.)

peristaltic action of the constrictor muscles of the esophagus (Ardran & Kemp, 1951; Fyke & Code, 1955; Mandelstam & Lieber, 1970). When the bolus has entered the esophagus, it is beyond the control of the clinician and no exercise program will affect esophageal swallowing disorders. Therefore, the speech-language pathologist's role is predominantly to effect changes in the first three phases of the swallow, that is, the oral preparatory, the oral, and the pharyngeal stages. It is important, however, that speech-language pathologists who are involved in the diagnosis and treatment of swallowing disorders be familiar with those disorders of the esophagus which can masquerade as oral or pharyngeal swallowing problems. Such disorders can cause reflux (backflow of food) from the esophagus into the pharynx, and coughing and choking behavior, which can be misinterpreted as a pharyngeal stage disorder (Kirchner, 1967).

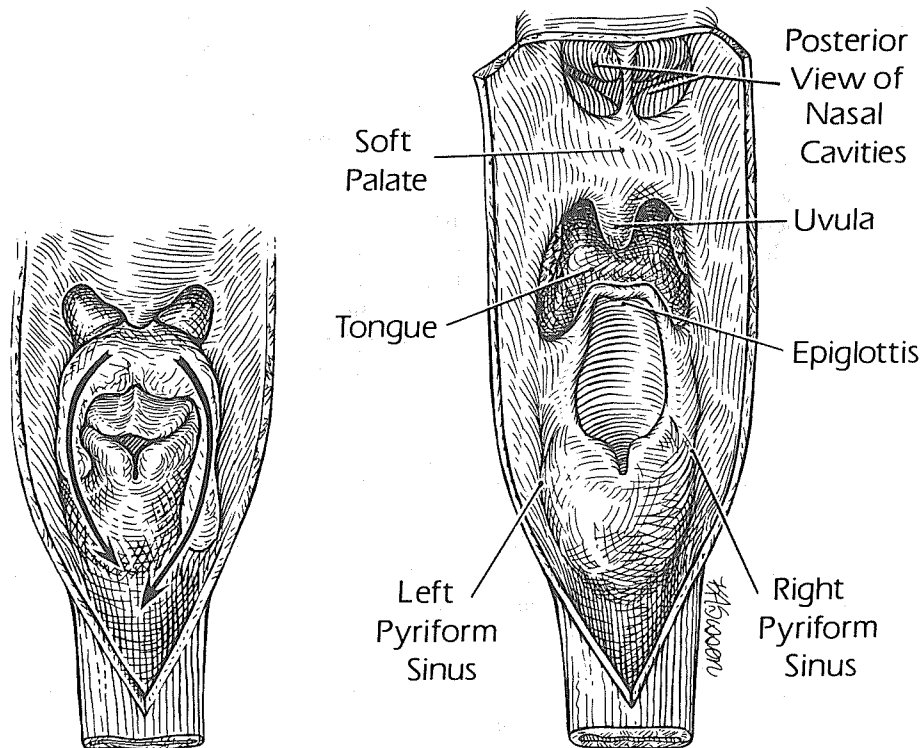


FIGURE 2. Posterior to anterior view of the pharynx, illustrating the pyriform sinuses, which are spaces created between the sides of the larynx and the pharyngeal constrictors. Arrows on portion (A) indicate the pathway of food and liquid down the pyriform sinuses on each side during the swallow. (From Logemann, 1983; © College-Hill Press, reprinted by permission.)

## SWALLOWING DISORDERS

Anatomic or physiologic swallowing disorders may occur in any phase of the swallow (Donner & Silbiger, 1974; Hurwitz, Nelson, & Haddad, 1975; Logan & Bosma, 1967; Logemann, 1983). In the oral preparatory phase, swallowing disorders include (a) incomplete lip closure; (b) reduction in tension in cheek musculature due to surgical or neurologic damage; (c) reduction in motion of lower jaw, usually from surgical or traumatic damage; and (d) reduction in range or coordination of tongue movement, which may be neurological, surgical, or traumatic in origin (Logemann, 1983).

Disorders in the oral stage of the swallow are similar to those in the oral preparatory phase. However, damage to tongue function may affect only one particular direction of movement, such as elevation of the tongue, or anterior/

posterior motion of the tongue. Both directions of tongue movement are necessary to perform the upward and backward propulsion of the bolus to initiate the swallow.

Disorders in the pharyngeal phase of the swallow may include (a) a delayed or absent triggering of the swallowing reflex resulting in food falling into the pharynx without any of the four neuromotor aspects of the pharyngeal phase occurring; (b) reduction in velopharyngeal closure resulting in reflux of material into the nasal cavity; (c) damage to pharyngeal peristalsis, either unilateral or bilateral, so that the squeezing action of the pharyngeal constrictors is inadequate to move the entire bolus through the pharynx and some food is left behind in the pharyngeal recesses after the swallow; (d) damage to the elevation of the larynx, which tucks it under the base of the tongue to divert material away from the top of the airway, resulting in some residue of food at the top of the airway *after* the swallow; (e) damage to laryngeal adduction, or airway closure, so that food can leak through the larynx into the airway *during* the swallow; and (f) damage to the cricopharyngeus muscle, so that it cannot open in a timely fashion or sufficiently to allow the bolus to pass into the esophagus, leaving food in the pyriform sinuses *after* the swallow (Calcaterra, Kadell, & Ward, 1975; Curtis & Hudson, 1983; Hurwitz et al., 1975; Logemann, 1983; Silbiger et al., 1967).

A number of these swallowing disorders in each aspect or stage of deglutition may cause aspiration or the entry of food into the airway below the true vocal cords. Aspiration can occur *before*, *during*, or *after* the reflexive swallow. *Before* the swallow, aspiration can occur if the patient loses control of food with his or her tongue during oral preparation, causing the food to drip into the pharynx before he or she can initiate a swallow. Or, aspiration can occur *before* the swallow because of a delayed triggering of the swallowing reflex when food falls into the pharynx while the airway is still open. Aspiration can occur *during* the swallow when food slips through the larynx which has not closed sufficiently. *After* the swallow, aspiration can occur when food remains in the pharynx for any of the reasons described above and is inhaled or falls into the airway as the patient takes a breath following the swallow.

## DIAGNOSTIC PROCEDURES

Diagnostic procedures for the assessment of swallowing disorders must be able to identify accurately the anatomy and physiology of all stages of the patient's swallow, and to identify those aspects of deglutition that are abnormal. Diagnostic techniques must also be able to identify aspiration and the etiology for the aspiration so that the etiology can be treated.

Currently, two techniques are widely used for the diagnosis of swallowing disorders: (a) a bedside evaluation and (b) a fluoroscopic examination called a modified barium swallow. The bedside evaluation is highly accurate in identifying disorders in the oral preparatory and oral aspects of deglutition. Much of the bedside evaluation procedure has been borrowed from the speech-language pathologist's traditional oral motor examination. Unfortunately, with our present technology the bedside evaluation is inaccurate in assessing pharyngeal aspects of degluti-

tion and in identifying aspiration and the etiologies of aspiration (Logemann, Lazarus, & Jenkins, 1982). The inaccuracy occurs because there are no techniques designed for use at the bedside which can accurately assess whether or not food has entered the airway. Some patients, particularly those with neurological impairments, may not cough or produce a gargley voice quality when food enters the airway (Linden & Siebens, 1983; Logemann, 1983). There are no data which correlate degree of laryngeal dysfunction on any measures with ability to protect the airway. Thus, there is no reliable way to assess whether a patient has aspirated at the bedside. In all likelihood, the bedside evaluation will become more accurate in the next few years as new techniques and measures are developed for indirect assessment of particular aspects of swallowing physiology at the bedside.

Because the bedside evaluation is so inaccurate, clinicians have turned to radiographic procedures for the assessment of swallowing disorders (Blonsky et al., 1975; Curtis & Hudson, 1983; Linden & Siebens, 1983; Logemann, 1983, in press). A fluoroscopic study can provide accurate information on the speed of the swallow (transit times) and on the presence and amount of any aspiration which may occur, as well as the anatomic or physiologic reason for any aspiration. In addition, it can provide information on the anatomy and physiology of the upper aerodigestive tract during deglutition. This information is critical to an accurate diagnosis and efficient management of the dysphagic patient. The fluoroscopic examination of deglutition, like a fluoroscopic study completed to assess speech functions, is performed by the speech-language pathologist together with a radiologist.

The modified barium swallow procedure has been developed to examine the oral-preparatory, oral, and pharyngeal aspects of deglutition radiographically. This procedure involves studying the patient's deglutition under normal physiologic conditions. Therefore, the patient is examined while he or she is seated upright and swallows a variety of food consistencies. Because patients with dysphagia often complain of difficulty swallowing particular food consistencies, each patient is given a small amount ( $\frac{1}{3}$  teaspoon) of liquid, paste or pudding, and chewable material (usually a fourth of a small cookie). The limited amount of material prevents significant aspiration and facilitates detailed observation of anatomy and physiology of the oral cavity and pharynx. The patient is initially viewed in the lateral plane, as shown in Figure 3, in order that the oral cavity and pharynx can be clearly viewed. The lateral view permits accurate measurement of oral and pharyngeal transit times, as well as accurate observation of any aspiration that may occur. If the patient is viewed in the anterior/posterior plane, the trachea and the esophagus overlap with one another so that it is difficult to assess aspiration. When two swallows of each food consistency have been examined in the lateral plane, the patient is turned and viewed in the anterior posterior plane in order to assess the symmetry of oral and pharyngeal control during the swallow. Then techniques to improve the patient's swallow, particularly postural changes (Logemann, in press), are usually attempted and assessed radiographically.

The disadvantage of the modified barium swallow procedure is that it exposes the patient to a small amount of radiation. Though the radiation dose is no more than the patient would receive in any other diagnostic radiology procedure, the clinician must still be cautious and not prolong the patient's exposure. In the years to come,



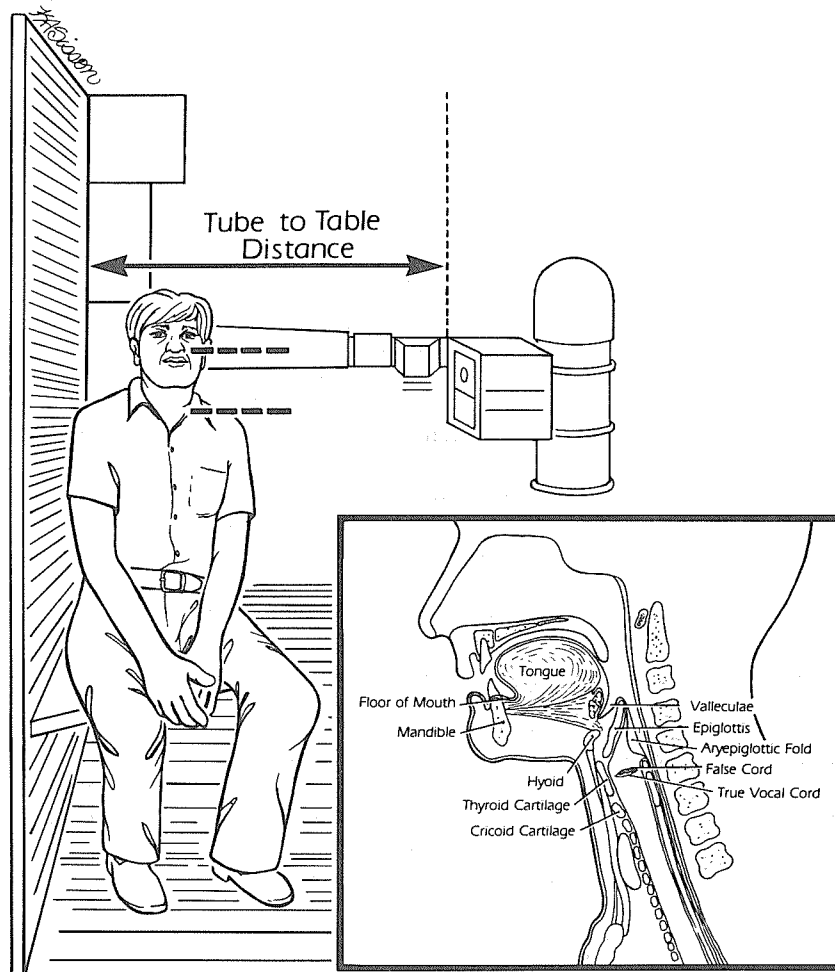


FIGURE 3. Patient seated on the platform attached to the fluoroscopy table so that the upper aero digestive tract can be viewed laterally, as shown in the inset in the lower right-hand corner. (From Logemann, 1983; © College-Hill Press, reprinted by permission.)

refined bedside assessment procedures will probably replace the need for radiographic procedures.

At the end of any diagnostic procedure the clinician writes a report describing the patient's swallowing disorder, the amount and etiology of any aspiration that has occurred on any swallows, treatment recommendations, and recommendations regarding the potential for oral feeding. The patient's attending physician then uses this information in decisions regarding the patient's nutritional management.

Other instrumental procedures have been used to examine more limited aspects of the deglutition process. Recently, ultrasound has been applied to the study of the oral-preparatory and oral stages of swallowing (Shawker, Sonies, Stone, & Baum, 1983; Sonies, 1982; Sonies & Shawker, 1983; Sonies, Stone, & Stone, 1984). Ultrasound imaging is noninvasive and does not expose the subject to any radiation. It uses regular liquids and like fluoroscopy can be performed in the lateral (sagittal) or anterior/posterior (coronal) positions. Unfortunately, the current limitations of ultrasound make its application to the study of the pharyngeal stage of deglutition impossible.

Manometry has been used for a number of years to study the esophageal aspect of swallowing and the intact nature of the upper (cricopharyngeus muscle) and lower esophageal sphincters (Fyke & Code, 1955; Hansky, 1973; Hurwitz et al., 1975). The patient swallows pressure-sensitive tubing which registers the changing pressures with muscle contraction and relaxation. The peristaltic wave in the pharynx and the esophagus can be examined. Unfortunately, manometry provides no information on aspiration, laryngeal function, or the oral or oral-preparatory phases of the swallow.

## PATIENTS WHO EXHIBIT SWALLOWING DISORDERS

A wide variety of patients exhibit swallowing disorders. Many patients with neurologic damage, either congenital (e.g., cerebral palsy and myotonic dystrophy) or acquired (e.g., CVA, head trauma, Parkinson's disease, or amyotrophic lateral sclerosis), exhibit swallowing disorders (Blonsky et al., 1957; Donner & Silbiger, 1974; Logan & Bosma, 1967; Silbiger et al., 1967). Many patients who have undergone surgical or radio therapy treatment for cancer of the head and neck region will exhibit swallowing problems posttreatment (Aguilar et al., 1979; Logemann & Bytell, 1979; Sessions, Zill, & Schwartz, 1979; Shedd et al., 1960). Some will exhibit swallowing disorders prior to treatment because of their tumor. Many premature infants exhibit disorders of sucking and swallowing, which may persist into early childhood (Logan & Bosma, 1967). Each of these cases of dysphagia requires careful and detailed evaluation and management.

## TREATMENT OF SWALLOWING DISORDERS

Treatment of swallowing disorders falls into three basic types: (a) compensatory strategies, (b) indirect swallowing therapy, and (c) direct swallowing therapy (Aguilar et al., 1979; Griffin, 1974; Groher, 1984; Logemann, 1983). Compensatory strategies include postural techniques and modifications of diet which facilitate the patient's oral feeding without changing the actual swallowing physiology. Both postural changes and limitations of food consistency affect the way food falls into and through the pharynx. These kinds of changes are often used as temporary

measures until recovery or improvement with therapy occurs in the damaged aspect(s) of swallowing physiology.

Indirect swallowing therapy involves exercises to improve selected aspects of neuromuscular control necessary to normal swallowing without actually asking the patient to swallow food. For example, lip closure, tongue elevation, retraction and shaping, and vocal fold adduction are all required for normal deglutition and can be practiced in isolation or in a dry swallow.

Direct swallowing therapy involves bringing the swallowing process to a conscious level and giving the patient specific instructions to follow in completing each swallow of a particular food consistency. The specific instructions used will vary from patient to patient and will depend on the exact nature of the patient's swallowing problem.

## RELATIONSHIP BETWEEN SPEECH AND SWALLOWING

The relationship between neuromotor control of speech and swallowing is unclear in many patients. There has been little research on these relationships. Much of the therapy focusing on early feeding strategies with cerebral-palsied youngsters assumes that oromotor control of food for feeding and swallowing is a prerequisite for neuromuscular control of these same structures for speech. Whether or not this is true may depend somewhat on the level and nature of the damage to the aero digestive tract. Clearly, patients with structural damage to the oral cavity, pharynx, or larynx, such as surgically treated head and neck cancer patients, can be expected to exhibit similar deficits in both speech and swallowing. That is, if they have difficulty in adducting the vocal folds to produce voice, they will also have difficulty closing the larynx to protect the airway for swallowing. If the patient has restricted tongue elevation because a part of the tongue has been removed surgically, he or she should have equal dysfunction during both speech and swallowing. Similarly, the neurologically impaired patient with damage to the peripheral nerves controlling muscles of the vocal tract can be expected to show similar functional patterns in both speech and swallowing. At the level of the brainstem, however, differences in neuromuscular control of both speech and swallowing may be seen. Swallowing involves reflexive control, whereas speech is under voluntary control. However, there is also cortical or voluntary input into triggering the swallowing reflex via the tongue activity which initiates the voluntary swallow. Though little is known about the neurophysiology of this interaction between voluntary and involuntary control (Miller, 1982), it is hoped that future research in this area will further our knowledge of both speech and swallowing motor control.

Speech-language pathologists working with dysphagic patients should have had coursework in the area and hands-on, supervised practicum. Those working with particular types of dysphagic patients will find similarities in the patients' functional deficits and in patterns of recovery across both speech and swallowing. It is for this reason that speech-language pathologists have become involved in the diagnosis and management of swallowing disorders as well as in dysphagia research. Our

ultimate understanding of normal and abnormal neuromuscular control of the vocal tract will depend on expansion of our knowledge regarding the overlapping voluntary and involuntary functions of the upper aero digestive tract.

#### REFERENCES

- AGUILAR, N., OLSON, M., & SHEDD, D. (1979). Rehabilitation of deglutition problems in patients with head and neck cancer. *American Journal of Surgery*, 138, 501-507.
- ARDRAN, G., & KEMP, F. (1951). The mechanism of swallowing. *Proceedings of the Royal Society of Medicine*, 44, 1038-1040.
- ARDRAN, G., & KEMP, F. (1956). Closure and opening of the larynx during swallowing. *British Journal of Radiology*, 29, 205-208.
- BLONSKY, E., LOGEMANN, J., BOSHES, B., & FISHER, H. (1975). Comparison of speech and swallowing function in patients with tremor disorders and in normal geriatric patients: A cinefluorographic study. *Journal of Gerontology*, 30, 299-303.
- BOSMA, J. (1957). Deglutition: Pharyngeal stage. *Physiological Reviews*, 37, 275-300.
- CALCATERRA, T., KADELL, B., & WARD, O. (1975). Dysphagia secondary to cricopharyngeal muscle dysfunction. *Archives of Otolaryngology*, 101, 726-729.
- CRUICKSHANK, W. (1966). *Cerebral palsy: Developmental disability*. Syracuse, NY: Syracuse University Press.
- CURTIS, D., CRUESS, D., DACHMAN, A., & MASO, E. (1984). *Timing in the normal pharyngeal swallow: Prospective selection and evaluation of sixteen normal asymptomatic patients*. Manuscript submitted for publication.
- CURTIS, D., & HUDSON, T. (1983). Laryngotracheal aspiration: Analysis of specific neuromuscular factors. *Radiology*, 149, 517-522.
- DONNER, M., & SILBICER, M. (1974). Cinefluorographic analysis of pharyngeal swallowing in neuromuscular disorders. *Seminars in Roentgenology*, 9, 273-282.
- DOTY, R., & BOSMA, J. (1956). An electromyographic analysis of reflex deglutition. *Journal of Neurophysiology*, 19, 44-60.
- FYKE, F., & CODE, C. (1955). Resting and deglutition pressures in the pharyngoesophageal region. *Gastroenterology*, 29, 24-34.
- GRIFFIN, K. (1974). Swallowing training for dysphagic adults. *Archives of Physical Medicine*, 55, 467-470.
- GROHER, M. (Ed.) (1984). *Dysphagia: Diagnosis and management*. Boston: Butterworth.
- HANSKY, J. (1973). The use of esophageal motility studies in the diagnosis of dysphagia. *Australian New Zealand Journal of Surgery*, 42, 360-361.
- HOLSTEGE, G., GRAVELAND, G., BIJKER-BIEMOND, C., & SCHUDEBOOM, I. (1983). Location of motoneurons innervating soft palate, pharynx and upper esophagus. Anatomical evidence for a possible swallowing center in the pontine reticular formation. *Brain Behavior and Evolution*, 23, 47-62.
- HURWITZ, A., NELSON, J., & HADDAD, J. (1975). Oropharyngeal dysphagia manometric and cine esophagographic findings. *Digestive Diseases*, 20, 313-323.
- KIRCHNER, J. (1967). Pharyngeal and esophageal dysfunction: The diagnosis. *Minnesota Medicine*, 50, 921-924.
- LINDEN, P., & SIEBENS, A. (1980, November). *Videofluoroscopy: Use in evaluation and treatment of dysphagia*. Mini seminar presented at the Annual Convention of the American Speech-Language-Hearing Association, Detroit.
- LINDEN, P., & SIEBENS, A. (1983). Dysphagia. Predicting laryngeal penetration. *Archives of Physical Medicine*, 64, 281-284.
- LOGAN, W., & BOSMA, J. (1967). Oral and pharyngeal dysphagia in infancy. *Pediatric Clinics of North America*, 14, 47-61.
- LOGEMANN, J. (1983). *Evaluation and treatment of swallowing disorders*. San Diego: College-Hill Press.
- LOGEMANN, J. (in press). *A manual for fluoroscopic examination of swallowing*. San Diego: College-Hill Press.

- LOGEMANN, J., & BYTELL, D. (1979). Swallowing disorders in three types of head and neck surgical patients. *Cancer*, 44, 1075-1105.
- LOGEMANN, J., LAZARUS, C., & JENKINS, P. (1982, November). *The relationship between clinical judgment and radiographic assessment of aspiration*. Paper presented at the Annual Convention of the American Speech-Language-Hearing Association, Toronto.
- MANDELSTAM, P., & LIEBER, A. (1970). Cineradiographic evaluation of the esophagus in normal adults. *Gastroenterology*, 58, 32-38.
- MILLER, A. (1982). Deglutition. *Physiological Reviews*, 62, 129-184.
- MORRIS, S. (1977). *Program guidelines for children with feeding problems*. Edison, NJ: Childcraft.
- NEGUS, V. (1949). The second stage of swallowing. *Acta Otolaryngologica*, 75(Suppl.), 78-82.
- POMMERENKE, W. (1928). A study of the sensory areas eliciting the swallowing reflex. *American Journal of Physiology*, 84, 36-41.
- ROBBINS, J., LOGEMANN, J., & KIRSHNER, H. (1982, November). *Velopharyngeal activity during speech and swallowing in neurologic disease*. Paper presented at the Annual Convention of the American Speech-Language-Hearing Association, Toronto.
- SESSIONS, D., ZILL, R., & SCHWARTZ, J. (1979). Deglutition after conservation surgery for cancer of the larynx and hyopharynx. *Otolaryngology and Head and Neck Surgery*, 87, 779-796.
- SESSLE, B., & HANNAN, A. (Eds.). (1976). *Mastication and swallowing*. Toronto: University of Toronto Press.
- SHAWKER, T., SONIES, B. C., STONE, M., & BAUM, B. (1983). Real-time ultrasound visualization of tongue movement during swallowing. *Journal of Clinical Ultrasound*, 11, 485-494.
- SHEDD, D., KIRCHNER, J., & SCATLIFF, J. (1961). Oral and pharyngeal components of deglutition. *Archives of Surgery*, 82, 371-380.
- SHEDD, D., SCATLIFF, J., & KIRCHNER, J. (1960). A cineradiographic study of post resectional alterations in oropharyngeal physiology. *Surgery, Gynecology and Obstetrics*, 110, 69-89.
- SILBINGER, M., PIKIELNEY, R., & DONNER, M. (1967). Neuromuscular disorders affecting the pharynx. Cineradiographic analysis. *Investigative Radiology*, 2, 442-448.
- SONIES, B. (1982). Oral imaging systems: A review and clinical applications: *Journal of the National Student Speech Language Hearing Association*, 10, 30-32.
- SONIES, B., & SHAWKER, T. (1983, May). *Ultrasonic visualization of tongue motion during swallowing*. Paper presented at the annual meeting of the Acoustical Society of America, Cincinnati.
- SONIES, B. C., STONE, T. H., & STONE, M. (1984). Speech and swallowing in the elderly. *Journal of Gerontology*, 3, 115-123.
- WESTLAKE, H., & RUTHERFORD, D. (1961). *Speech therapy for the cerebral palsied*. Chicago: National Society for Crippled Children and Adults.